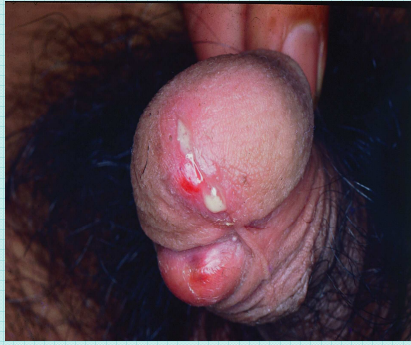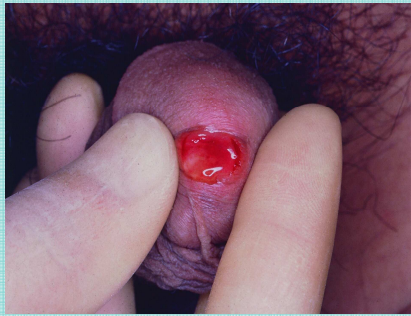


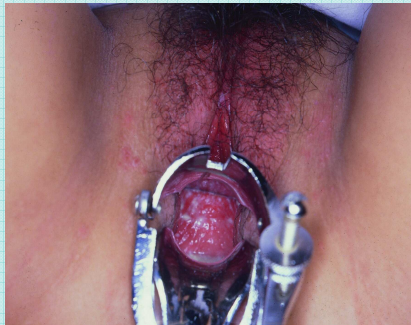DISCHARGES



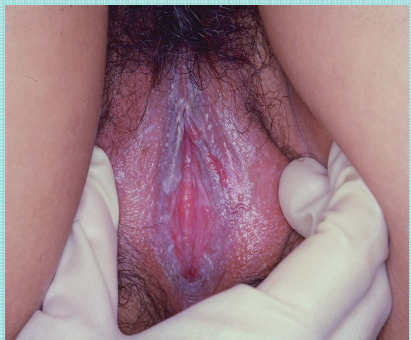Mucopurulent discharge suggestive of gonorrhea.



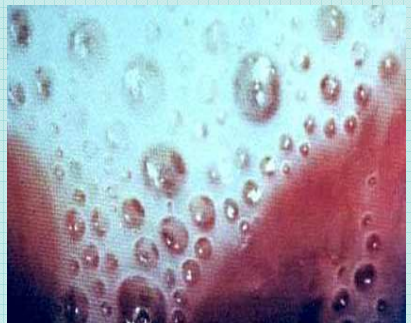Scanty mucoid discharge generally suggestive of *Chlamydia trachomatis* and *Mycoplasma* spp.



Cheesy white discharge suggestive of *Candida* spp.



Whitish, thin, homogenous, adherent and foul smelling discharge suggestive of *Gardenerella vaginalis*.



Frothy, foul smelling discharge suggestive of *Trichomonas vaginalis*.